

## A CONSENSUS ON RISK MITIGATION FOR BROLUCIZUMAB IN NEOVASCULAR AGE-RELATED MACULAR DEGENERATION

### Patient Selection, Evaluation, and Treatment

FRANK G. HOLZ, MD,\* TOMOHIRO IIDA, MD,† ICHIRO MARUKO, MD,† SRINIVAS R. SADDA, MD‡

---

**Purpose:** Brolucizumab has high efficacy in retinal fluid resolution and provides the possibility for longer dosing intervals in the treatment of neovascular age-related macular degeneration. However, brolucizumab has been associated with events of retinal vasculitis and retinal vascular occlusion typically in the presence of other signs of intraocular inflammation (IOI). The purpose of this report is to provide guidance on the use of brolucizumab for neovascular age-related macular degeneration to a global audience.

**Methods:** A literature review was conducted on adverse events related to IOI after administration of brolucizumab in eyes with neovascular age-related macular degeneration.

**Results:** Possible risk factors for IOI and retinal vascular occlusion after brolucizumab should be considered before administering brolucizumab. Patients who receive brolucizumab should be educated on the symptoms, signs, and time course of IOI after brolucizumab. Before each injection of brolucizumab, physicians should assess the eye for any signs of inflammation and not treat with brolucizumab if inflammation is detected. Treatment of IOI should be prompt and provided with particular attention to the posterior segment.

**Conclusion:** Careful patient selection, patient education, assessment for inflammation, and intensive treatment of possible inflammation are important when using brolucizumab in patients with neovascular age-related macular degeneration.

RETINA 42:1629–1637, 2022

---

High intravitreal injection burden and nonadherence are major challenges in the treatment of patients with neovascular age-related macular degeneration (nAMD).<sup>1,2</sup> In a recent analysis of real-world data from the Intelligent Research in Sight (IRIS) registry, almost 40% of patients received injections more frequently than every 8 weeks at the 1-year follow-up.<sup>3</sup> A global survey of patients and caregivers identified treatment burden as one of the major challenges for nAMD and among the major reasons for nonadherence.<sup>4</sup> Data from a systematic review identified nonadherence as a prevalent problem, with up to 57% of patients nonadherent to treatment at 12 months.<sup>5</sup> Given that undertreatment represents a risk of long-term vision loss,<sup>6</sup> these data

suggest there is a need for durable treatments that reduce treatment burden.

Brolucizumab is an anti-vascular endothelial growth factor (VEGF) agent that launched in 2019 for the treatment of nAMD.<sup>7</sup> In the phase 3 HAWK and HARRIER studies, visual acuity gains at Week 48 with brolucizumab (q8 or q12 weeks) were noninferior to aflibercept (q8 weeks).<sup>8</sup> Rates of retinal fluid presence were lower with brolucizumab than with aflibercept (Figure 1). Furthermore, approximately half of brolucizumab-treated eyes (55.6% and 51.0% in HAWK [6 mg] and HARRIER, respectively) were maintained on a 12-week dosing regimen, suggesting that brolucizumab provides the possibility for greater intervals between injections. Brolucizumab was

reported to be generally well tolerated,<sup>8</sup> although the incidence of intraocular inflammation (IOI) was higher with brolocizumab 6 mg (HAWK: 5.3%; HARRIER: 2.7%) than with aflibercept (HAWK: 0.3%; HARRIER: 0.8%).<sup>9</sup> Based on these studies, brolocizumab has received approval in more than 40 regions worldwide.<sup>10,11</sup>

In 2020, the American Society of Retina Specialists circulated safety updates regarding cases of retinal vasculitis (RV) in patients treated with brolocizumab, some of which were reported as occlusive RV with associated vision loss.<sup>12</sup> The postmarketing reporting rate for RV and/or retinal vascular occlusion (RO) has been approximately 15.1 per 10,000 injections (as of August 27, 2021).<sup>12</sup> To better understand these reports, Novartis commissioned an external Safety Review Committee (SRC) to reassess cases of IOI, endophthalmitis, and retinal artery occlusion among brolocizumab-treated eyes in HAWK and HARRIER.<sup>13</sup> Of the 60 eyes evaluated, the SRC reported, 50 eyes (50/1,088; 4.6%) had definite or probable events that were drug-related and in the spectrum of IOI, RV, and/or RO.<sup>13</sup> Of

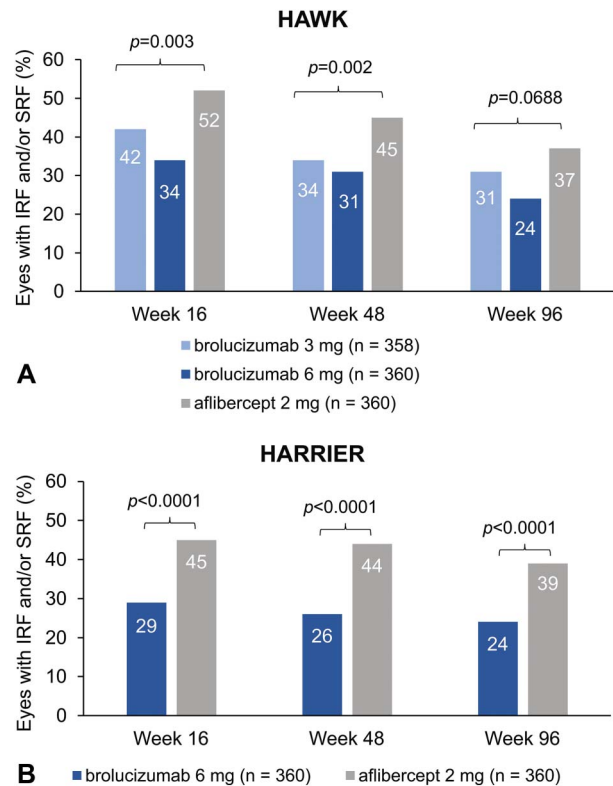
From the \*Department of Ophthalmology, University of Bonn, Bonn, Germany; †Department of Ophthalmology, Tokyo Women's Medical University, Tokyo, Japan; and ‡Department of Ophthalmology, University of California, Los Angeles, David Geffen School of Medicine, Los Angeles, California

Medical writing support was funded by Novartis Pharma AG (Basel, Switzerland). F.G. Holz reports research grants and personal fees from Acucela, Allergan, Apellis Pharmaceuticals, Bayer, Bioeq/Formycon, Chengdu Kanghong Pharmaceutical Group, Geuder, Heidelberg Engineering, IVERIC bio, Novartis, Roche/Genentech, and Zeiss and personal fees from Boehringer Ingelheim, Graybug Vision, Lin BioScience, Pixium Vision, Stealth BioTherapeutics, Aerie, and Oxurion. T. Iida received grants from NIDEK (Japan) and Senju Pharmaceutical (Japan); grants and personal fees from Alcon Pharma (Japan) and Santen Pharmaceutical (Japan); and personal fees from Bayer Yakuhin (Japan). T. Iida also received research support from Canon (Japan), Kowa Pharmaceuticals (Japan), and Topcon (Japan) outside the submitted work. I. Maruko received grants from Japan Society for the Promotion of Science KAKENHI (Grant Number JP20K09781); grants and personal fees from Alcon Pharma; and personal fees from Bayer Yakuhin, Santen Pharmaceutical, Alcon Japan, Topcon, Senju Pharmaceutical, and NIDEK outside the submitted work. S.R. Sadda reports being a consultant for Allergan/AbbVie, Amgen, Apellis Pharmaceuticals, CenterVue, 4D Molecular Therapies, Heidelberg Engineering, IVERIC Bio, Nanoscope Therapeutics, Novartis, Optos, Oxurion, Regeneron Pharmaceuticals, and Roche/Genentech and research instruments from CenterVue, Carl Zeiss Meditec, Heidelberg Engineering, Nidek, Optos, and Topcon.

None of the authors has any financial/conflicting interests to disclose.

This is an open access article distributed under the terms of the Creative Commons Attribution-Non Commercial-No Derivatives License 4.0 (CCBY-NC-ND), where it is permissible to download and share the work provided it is properly cited. The work cannot be changed in any way or used commercially without permission from the journal.

Reprint requests: Frank Holz, MD, Department of Ophthalmology, University of Bonn, Ernst-Abbe-Strasse 2, Bonn D-53127, Germany; e-mail: frank.holz@ukbonn.de



**Fig. 1.** The percentage of eyes with presence of IRF and/or SRF at Week 16, 48, and 96 in the HAWK study (A) and in the HARRIER study (B). One-sided *p* values are shown for Week 16 and 48. Two-sided *P* values are shown for Week 96. Adapted from Dugel PU, Singh RP, Koh A, et al. *Ophthalmology*. 2021;128(1):89–99, with permission from Elsevier.

these 50 eyes, 36 had concomitant RV (3.3%), of which 23 had concomitant RO (2.1%). The overall rate of at least moderate vision loss ( $\geq 15$  Early Treatment Diabetic Retinopathy Study letters) by Week 96, however, was comparable between brolocizumab 6 mg and aflibercept in both HAWK (8.1% vs. 7.4%) and HARRIER (7.1% vs. 7.5%).<sup>8</sup> Based on the safety findings, a label update was approved by several health authorities.<sup>12</sup> In 2021, Novartis issued a statement that physicians should not administer brolocizumab at intervals less than 2 months beyond the first three doses (i.e., dosing intervals should be 8 weeks or more during the maintenance phase), based on the safety findings from the first interpretable 1-year results of the phase three MERLIN study, in which brolocizumab was administered every 4 weeks. In MERLIN, the rates of IOI for brolocizumab and aflibercept were 9.3% versus 4.5%, the rates of RV were 0.8% versus 0.0%, the rates of RO were 2.0% versus 0.0%, and the rates of vision loss  $\geq 15$  letters from all causes were 4.8% versus 1.7%.<sup>12</sup>

Several case reports and case series have described events of RV and/or RO associated with brolocizumab.<sup>14–23</sup> A comprehensive table of case study reports

Table 1. Summary of Recent Global Case Studies and Case Series of IOI, Retinal Vasculitis, and Retinal Vascular Occlusive Events after Intravitreal Brolucizumab Treatment in Patients With nAMD

Study	N	Presenting Symptoms	Examination Findings	Treatment	Resolution
Angerer, 2020 <sup>35</sup>	1 eye	Swollen eyelids and foreign body sensation initially; eye pain and vision loss	Vision was 1/30 on hand chart (from 0.05), internal pressure of 33 mm Hg, moderate Descemet folds, AC cells, fundus view was reduced, and choroidal detachment	Ofloxacin eye drops TID initially; intravenous aciclovir 500 mg TID, prednisolone acetate eye drops 5 times daily; switch to 900-mg oral valganciclovir BID (because of initial suspicion of herpes zoster-associated uveitis); subsequently, parabulbar administration of fortecortin and systemic prednisolone 100 mg daily	Pale optic disc, "ghosting" of the central arteries, obliterations of retinal vessels in the periphery, intraretinal bleeding. Vision no longer increased
Iyer 2020 <sup>19</sup>	1 eye	Pain, ocular aches, floaters, and decreased vision	VA decreased from 20/70–20/200, AC cells (0.5+), vitreous debris, arterial plaques, vascular sheathing, boxcarring, and retinal whitening; subsequently, VA decreased to count fingers at 3 feet, fine keratic precipitates, AC cells (2+), posterior debris and haze, and worse retinal whitening	Topical 1% prednisolone acetate; subsequently, 0.05% difluprednate drops every 2 hours and oral high-dose methylprednisolone pulse therapy, pars plana vitrectomy with intravitreal triamcinolone injection	Vision improved to 20/200
Antaki 2021 <sup>20</sup>	1 eye	Pain, vision loss	VA reduced to light perception (from 20/150), moderate to severe vitritis, arterial sheathing, diffuse arterial and venous narrowing, perivenular hemorrhages, filling defects, and peripheral nonperfusion	—	—
Enriquez 2021 <sup>36</sup>	14 eyes of 13 patients	Symptoms of 1 patient described: floaters and blurred vision	IOI with anterior segment and/or vitreous cells	Topical and/or oral corticosteroids, sub-Tenon triamcinolone acetamide, vitrectomy, and/or intraoperative triamcinolone; or no treatment	11 eyes switched to a different anti-VEGF
Hikichi, 2021 <sup>21</sup>	3 eyes of 3 patients	Ocular redness, pain, and decreased vision	BCVA decreased to 0.3 (from 1.2), ciliary hyperemia, AC (1+) cells, fine keratic precipitates without fibrin material, anterior vitreous cells (2+), slight vitreous haze; subsequently, hypopyon and vitreous opacities, BCVA decreased to HM	Topical 0.01% betamethasone sodium phosphate QID; subsequently, sub-Tenon 20 mg triamcinolone acetamide	Anterior chamber inflammation resolved; subsequently, hypopyon resolved, vitreous opacities decreased with improved BCVA to 0.5
		Ocular pain, redness, and blurred vision	BCVA decreased to 0.06 (from 0.3), conjunctival hyperemia, AC cells (1+), fine keratic precipitates, vitreous cells, vitreous opacities, intraretinal hemorrhage, vitreous haze, and sheathed inferior and inferotemporal retinal veins	Topical 0.01% betamethasone sodium phosphate QID and sub-Tenon 20-mg triamcinolone acetamide	Anterior chamber inflammation resolved, vitreous opacities decreased, BCVA recovered to 0.3, resolution of retinal hemorrhage, and reduction of the sheathed retinal vessels
		Floater and gradual progression to blurry vision without redness or pain	BCVA decreased to 0.6 (from 0.7), no ciliary hyperemia, rare AC cells, fine keratic precipitates, some vitreous opacities, sheathed retinal arteries and veins, and IRF and SRF recurrence	Topical 0.01% betamethasone sodium phosphate QID and sub-Tenon 20-mg triamcinolone acetamide injection	Vitreous opacities resolved, BCVA recovered to 0.7, and sheathed retinal vessels seemed to improve

(continued on next page)

Table 1. (Continued)

Study	N	Presenting Symptoms	Examination Findings	Treatment	Resolution
Kataoka, 2021 <sup>22</sup>	3 eyes of 3 patients	Blurry vision described as “white out”	VA reduced to 0.1 (from 0.6), AC cells (1+), fine keratic precipitates, vitreous cells (1+), no hypopyon, aqueous flare, vitreous haze, sheathing of peripheral retinal arteries and veins, blot retinal hemorrhage, leakage from veins at arcades and the peripheral retina, leakage from optic nerve head, and appearance of subretinal hyperreflective material	Oral prednisolone 30 mg per day and sub-Tenon triamcinolone acetonide injection (20 mg/0.5 mL) and 0.1% betamethasone eye drops QID	Vascular sheathing disappeared, no evidence of inflammation on FA, subretinal hyperreflective material decreased, VA recovered to 0.8, and aqueous flare decreased to levels comparable with fellow eye
		Floater	AC cells (1+), fine keratic precipitates, vitreous cells (1+), aqueous flare, vitreous haze, sheathing on peripheral retinal arteries and veins, blot retinal hemorrhage, filling defects, areas of nonperfusion in the peripheral retina, and segmental leakage in peripheral veins; subsequently, VA worsened from 0.5 to 0.3	Oral prednisolone 30 mg per day, sub-Tenon triamcinolone acetonide injection (20 mg/0.5 mL), and 0.1% betamethasone eye drops QID	Vascular sheathing disappeared, VA recovered to 0.5, aqueous flare decreased to levels comparable with fellow eye, and no evidence of inflammation on FA
		Blurry vision, floaters, and redness	VA reduced to 0.6 (from 1.5), slight conjunctival injection, AC cell (1+), fine keratic precipitates, vitreous cell (2+), thick vitreous opacities, blot hemorrhage in the peripheral retina, filling defects in the peripheral retinal arteries and veins, an area of nonperfusion in the peripheral retina, and diffuse leakage from retinal vessels and optic nerve head; subsequently VA worsened to 0.3	Oral prednisolone 30 mg per day, sub-Tenon triamcinolone acetonide injection (20 mg/0.5 mL), and 0.1% betamethasone eye drops QID	Decreased leakage, VA recovered to 1.5, improvement in vitreous haze, and disappearance of retinal hemorrhage
Kaupke, 2021 <sup>37</sup>	1 eye	VA loss that had persisted for 2 days, redness, and feeling of pressure	AC cells and conjunctival injection; subsequently, VA reduced to HM from 0.1, retinal hemorrhages, and increased AC irritation	Dexamethasone and gentamicin eye drops QID; subsequently, prednisolone 40 mg increased to 100 mg for 3 days	5 months after first presentation, the eye was completely blind and showed retinal atrophy
Kessler, 2021 <sup>30</sup>	2 eyes of 1 patient	“Thundercloud” appearance OS after first brolicizumab injection; vision loss OU after second brolicizumab injection	BCVA was 0.1 OD and 0.05 OS, granulomatous precipitates, pronounced AC flare, and numerous vitreous cells. Vision OS was blurred, and ischemia of the upper hemisphere of the retina was visible. Vessels showed leakage in OU	Vitrectomies with subsequent intravitreal dexamethasone implants OU; intravenous methylprednisolone 1 g for 3 days, 500 mg for 2 days, and 100 mg for the final 6 days; local prednisolone acetate hourly and ofloxacin QID; oral cortisone therapy	No renewal of inflammation and subsequently VA stabilized OU at 0.32
Leclaire, 2021 <sup>38</sup>	1 eye	Pain and visual deterioration	BCVA decreased to 1/15 m (from 0.4), AC cells, deposits on the endothelium, vitreous opacities, perivascular leakage, nonperfused areas, and vascular occlusions	Intravenous prednisolone 80 mg daily	AC and vitreous cleared, BCVA improved to 0.125, and perivascular ischemia was visible over the vascular arches

Table 1. (Continued)

Study	N	Presenting Symptoms	Examination Findings	Treatment	Resolution
Maruko, 2021 <sup>23</sup>	12 eyes of 12 patients	—	IOI consisting of AC cells and/or vitreous cells (12 eyes), with IOI + RV in 4 eyes and IOI + RV + RO in 2 eyes. RO was located outside the vascular arcades	IOI was treated with 0.1% betamethasone eye drops; RV was treated with sub-Tenon injection of triamcinolone acetonide 20 mg	VA decreased from 74 ETDRS letters to 35, then improved to 65 in 1 eye with RO. VA decreased from 59 letters to 50, then recovered to 65 in the other eye with RO
Narayanan, 2021 <sup>39</sup>	1 eye	Loss of vision, mild pain, redness	VA reduced to HM (from 20/250), minimal conjunctiva congestion, no lid edema, and 1-mm hypopyon, intense vitritis. Microbiological testing and polymerase chain reaction were negative	Topical steroids administered hourly, vitrectomy biopsy with intravitreal ceftazidime and vancomycin, topical moxifloxacin 6 times daily, prednisolone acetate hourly, and homatropine eye drops TID	Inflammation resolved significantly, and fundus details were visible. No evidence of vasculitis. VA improved to 20/600
Riedel, 2021 <sup>31</sup>	2 eyes of 1 patient	VA reduced to 0.2 OD (from 0.5) and HM OS (from 0.63)	Vitreous cells, papilledema, thin partly white arteries, cotton-wool spots, bleeding along vessels, highly reflective band in the outer plexiform layer, delayed retinal filling, prolonged arteriovenous passage time, and vascular occlusion	Oral prednisolone 50 mg, oral esomeprazole 40 mg, dexamethasone drops QID, and dorzolamide hydrochloride drops BID. OS also received intravitreal dexamethasone through implant	VA improved to 0.5 OD and 1/35 of a meter OS

AC, anterior chamber; BCVA, best-corrected visual acuity; BID, 2 times per day; ETDRS, Early Treatment Diabetic Retinopathy Study; FA, fluorescein angiography; HM, hand motion; IOI, intraocular inflammation; IRF, intraretinal fluid; OD, right eye; OS, left eye; OU, both eyes; QID, 4 times per day; RO, retinal vascular occlusion; RV, retinal vasculitis; SRF, subretinal fluid; TID, 3 times per day; VA, visual acuity.

was provided by Baupal et al.<sup>10</sup> Based on these data, it seemed that a variety of treatments were administered, including topical, intravitreal, sub-Tenon, and systemic corticosteroids. Baupal et al recommended frequent monitoring of patients with IOI for RV and RO and early and intensive treatment for RV and RO. Additional case reports and case series published globally since then are summarized in Table 1. Given that the events can result in vision loss, these cases highlight that early and aggressive therapy is warranted. Guidance on the use of brolocizumab for nAMD has been provided in the literature by several investigators.<sup>10,24,25</sup> Since these publications, more insight has emerged from retrospective analysis of real-world evidence from the IRIS Registry and Komodo Healthcare Map and post hoc analyses of the treatment of IOI-related adverse events in HAWK and HARRIER, enabling refinement of recommendations.<sup>26,27</sup> In this report, we provide guidance on best practices for the use of brolocizumab for nAMD based on our current understanding of the adverse events and expert opinion.

### Considerations for Treating With Brolocizumab

*Identification of patients for treatment with brolocizumab.* The decision to use brolocizumab in a patient with nAMD is based on a benefit–risk assessment. Brolocizumab has been shown to have a benefit in reducing retinal fluid and to allow for

12-week dosing intervals in some patients; however, the risk of RO and vision loss after brolocizumab must be considered.<sup>8,13,28,29</sup> It is notable that despite RV and RO events after brolocizumab, the rates of moderate vision loss were similar between brolocizumab- and aflibercept-treated patients,<sup>28</sup> highlighting that inadequate control of exudation may also be an important cause of vision loss, and this must be considered during treatment decision-making. Risk of IOI-related adverse events after brolocizumab has been estimated from the incidence of these events in clinical trials and real-world databases.<sup>13,27</sup> According to the post hoc analysis of HAWK and HARRIER by the SRC, the rate of RO after brolocizumab was 2.1% (23/1,088), and the rate of any form of IOI and losing 15 or more letters after brolocizumab was 0.7% (8/1,088).<sup>13</sup> According to retrospective analyses of the IRIS Registry and Komodo Healthcare Map, the incidences of RV and/or RO after administration of brolocizumab were 0.6% with up to 6 months of follow-up.<sup>27</sup> No significant difference was found between treatment-naïve eyes and eyes that were switched from another anti-VEGF in rates of IOI-related adverse events after brolocizumab.<sup>23,27</sup> In addition to the general incidence of these events, risk factors for IOI and RO should be considered to help indicate possible increased risk of RO for certain patients. The post hoc analysis of HAWK and HARRIER found that female sex and Japanese ethnicity were possible risk factors

for IOI after brolocizumab.<sup>23</sup> Retrospective analyses of the IRIS Registry and Komodo Healthcare Map replicated the finding of female sex as a potential risk factor for IOI and/or RO (IRIS: odds ratio [OR] = 2.23) and for RV and/or RO (IRIS: OR = 2.89) after brolocizumab.<sup>27</sup> Risk of RV and/or RO was estimated to be 0.65% for women versus 0.22% for men (IRIS).<sup>27</sup> In addition, history of IOI and/or RO within the 12 months before the initiation of brolocizumab was found to be a potential risk factor for IOI and/or RO (IRIS: OR = 4.69) and for RV and/or RO (IRIS: OR = 12.53) after brolocizumab.<sup>27</sup> Risk of RV and/or RO among those with previous IOI and/or RO compared with those without previous IOI and/or RO was 3.97% versus 0.32% (IRIS).<sup>27</sup> These findings suggest history of IOI or RO is a relatively strong risk factor for RV and/or RO. Physicians should inquire about a patient's history of IOI and RO for the benefit–risk assessment. The consequences of vision loss after brolocizumab for a particular eye should also be considered. For instance, patients with poor vision in the fellow eye may have a different perspective than those with good vision in the fellow eye. The risk of bilateral vision loss after brolocizumab should also be acknowledged when conducting a benefit–risk assessment for bilateral injections.<sup>30,31</sup> Importantly, the patient's preferences should be considered when deciding whether to use brolocizumab.

#### *Patient Counseling and Education*

Before initiation of treatment with brolocizumab, the risk of RO and vision loss after brolocizumab should be explained to the patient along with an explanation that the RO typically occurs in the presence of other signs of IOI.<sup>7,15</sup> Patients should be educated on the signs and symptoms associated with IOI after brolocizumab and the importance of immediately returning to the clinic if the patient experiences such signs or symptoms. Signs and symptoms reported in patients who developed RV and RO after brolocizumab have included reduced or blurred vision, floaters, pain or discomfort, redness, and scotoma.<sup>14,15,21,22</sup> Signs and symptoms reported in recent cases of IOI after brolocizumab are shown in Table 1. The likely time course of symptom onset from the last brolocizumab injection is also important for patient education. In a post hoc analysis of HAWK and HARRIER, the median time to the onset of the IOI-related adverse event was 25.5 days (range = 1–91) in patients who received brolocizumab.<sup>13</sup> Similarly, a postmarketing study of 26 eyes with RV after administration of brolocizumab found that the mean time to presentation of the adverse event was 26 days (range = 3–63).<sup>15</sup> Based

on these findings, IOI symptoms after brolocizumab may develop anytime between injections.

#### *Follow-up Visits*

For patients who receive brolocizumab, it has been considered that additional follow-up visits beyond those required for monitoring and treatment of nAMD may help increase the likelihood of early detection of IOI and RO; however, additional visits work against the purpose of using brolocizumab to reduce treatment burden. As an alternative, thorough patient education, in addition to examining for IOI and RO at visits for nAMD, may be adequate if the patient knows to return to the clinic immediately on experiencing symptoms of IOI. Physicians may consider having a clinical staff member call the patient to conduct a screening for symptoms of IOI as a supplement to patient education. Prophylaxis for IOI has also been suggested as a possible way to avoid the need for additional follow-up visits; however, there is no evidence to support the effectiveness of prophylaxis for IOI or RO after brolocizumab. Furthermore, because most patients will never develop IOI or RO, this would involve administering prophylaxis to many patients who will never develop these adverse events.

#### *Preinjection Assessment and Evaluation of Intraocular Inflammation*

Before each injection of brolocizumab, it is important to assess the patient for signs of inflammation using a dilated slit-lamp examination, dilated funduscopy, and optical coherence tomography because brolocizumab is contraindicated in the presence of active IOI.<sup>7,32</sup> Although the majority of IOI cases after brolocizumab (74%) were found to occur in the first 6 months of treatment in HAWK and HARRIER, 14% occurred between 6 and 12 months, and an additional 12% of cases occurred after 12 months.<sup>13</sup> Therefore, physicians should remain vigilant for signs of inflammation even after the first 6 months. Additional data are required to verify whether most IOI cases occur in the first 6 months. Full characterization of the location and severity of the inflammation, including the use of wide-field imaging and angiography, should be conducted to guide treatment decisions.<sup>10,24</sup>








Signs of IOI have been found in the anterior and/or the posterior segments in postmarketing studies of RV after brolocizumab. In a study of 26 eyes of 25 patients with RV after brolocizumab, IOI at presentation was found to be only anterior for 31% of eyes, only posterior for 27%, and both anterior and posterior for 35%. In 8% of eyes, IOI manifested only as RV.<sup>15</sup> In another study of 15 eyes from 12 patients with RV,

vitreous cells or opacities were observed in all eyes, and anterior chamber cells were observed in most eyes (73%).<sup>14</sup> Anterior findings also included fine keratic precipitates, Descemet folds, flare, and corneal edema.<sup>14</sup> Various features of RV and RO have been reported after brolocizumab, including vascular sheathing, boxcarring, narrowing, and occlusion, as well as filling defects, staining, choroidal hypofluorescence, and optic nerve leakage.<sup>14,15,21,22</sup> IOI after brolocizumab is considered more severe if there is RV and even more severe if there is RO.<sup>14</sup> Occlusions may affect the macula and/or the peripheral retina.<sup>14,15</sup>

Conditions to consider in the differential diagnosis of IOI after brolocizumab include infectious endophthalmitis and systemic diseases that may trigger RV.<sup>10,18</sup> One important differentiating characteristic between infectious endophthalmitis and IOI after brolocizumab is that infectious endophthalmitis presents on average 3 to 4 days from the last intravitreal injection, whereas IOI after brolocizumab has been found to present on average approximately 26 days from the last intravitreal injection.<sup>13,15,33</sup> However, the timing of presentation may not always distinguish between these conditions, and initial signs may be similar making the distinction challenging.<sup>10,24</sup>

*Treatment of Intraocular Inflammation and Retinal Vascular Occlusion After Brolocizumab*

The following treatment recommendations for IOI or RO after brolocizumab are the opinions of the authors. Treatment of IOI or RO after brolocizumab should be prompt and intensive.<sup>10</sup> If any inflammation or RO is detected, brolocizumab should be discontinued and treatment for nAMD should be resumed with a different anti-VEGF agent when medically appropriate. This is a conservative approach, given that IOI does not always progress to RO.<sup>13</sup> For inflammation confined to the anterior chamber, frequent administration of potent topical corticosteroids may be adequate to control the inflammation; however, there is the risk that inflammation will develop in the posterior segment of the eye,<sup>18</sup> in which case topical corticosteroids would not suffice. Therefore, careful monitoring of the posterior segment for the development of inflammation is necessary, and administration of intravitreal, sub-Tenon, or systemic corticosteroids may be considered to address the potential development of posterior segment inflammation.<sup>21,22,26</sup> If posterior segment inflammation is suspected or detected, intravitreal, sub-Tenon, or systemic corticosteroids should be

	<b>Pre-injection procedures and assessments</b>	Patient history of IOI; slit lamp, dilated funduscopy, OCT to assess for inflammation
	<b>Patient education</b>	Patients should monitor for any signs or symptoms of IOI, specifically reduced or blurred vision, floaters, pain, discomfort, redness, or scotoma
	<b>Assessments at follow-up/prior to next injection</b>	Slit lamp, dilated funduscopy including the peripheral retina, and OCT Assess anterior and posterior segments for inflammation (cells and haze)
	<b>For patients presenting with signs or symptoms of IOI</b>	Fluorescein angiography (wide field or peripheral images) Look for anterior or posterior inflammatory cells, perivascular sheathing, boxcarring, vascular occlusion, retinal vascular staining, leakage, filling defects, keratic precipitates, conjunctival injection, Descemet's folds, and corneal edema <i>Rule out infectious endophthalmitis (if unclear, treat with antibiotics and consider surgical intervention with vitrectomy)</i>
	<b>Actions, treatment</b>	Promptly treat inflammation with anti-inflammatory course as recommended below and monitor for any progression to or within the posterior segment
<div style="display: flex; justify-content: space-between;"> <div style="width: 45%; background-color: #0056b3; color: white; padding: 5px; border-radius: 10px;">  <p style="text-align: center; margin: 0;"><b>ANTERIOR UVEITIS</b></p> <ul style="list-style-type: none"> <li>Topical corticosteroids</li> <li>Frequent administration in the beginning; taper upon improvement; adjust dosage to individual needs</li> <li>If no response to topical therapy is seen or if inflammation spreads to the vitreous cavity and the posterior segment is involved, systemic, intravitreal, and/or sub-Tenon's treatment is recommended</li> </ul> </div> <div style="width: 45%; background-color: #0056b3; color: white; padding: 5px; border-radius: 10px;">  <p style="text-align: center; margin: 0;"><b>INTERMEDIATE UVEITIS, POSTERIOR UVEITIS and RETINAL VASCULITIS</b></p> <ul style="list-style-type: none"> <li>For the acute stage of intermediate uveitis, systemic (oral or, if necessary, intravenous) corticosteroids for ~6 to 12 weeks; gradually tapered to a maintenance dose if needed</li> <li>Intravitreal or sub-Tenon's steroids should be considered, especially if systemic corticosteroid therapy is contraindicated</li> <li>If the vitreous is heavily involved, a pars plana vitrectomy can be considered</li> </ul> </div> </div>		

**Fig. 2.** Recommendations for assessment, patient education, and management for IOI after brolocizumab based on the authors' opinions. Anterior uveitis, intermediate uveitis, and posterior uveitis are defined according to the SUN working group.<sup>34</sup>

administered. In case studies of RV or RO after bro-lucizumab, visual acuity returned to that observed before treatment with bro-lucizumab and sheathing of retinal vessels improved after injection of corticoste-roids into the sub-Tenon capsule with or without oral corticosteroids.<sup>21,22</sup> Other treatment methods would need to be considered for patients in whom corticoste-roids are not tolerated or are contraindicated. Post hoc analyses of HAWK and HARRIER found that IOI-related events were typically treated with topical corticosteroids, and intraocular or systemic corticoste-roids were rarely administered.<sup>26</sup> Therefore, it is currently unknown what the approximate rates of RO and vision loss from bro-lucizumab would be with more intensive treatment of IOI. A summary of the authors' recommendations, based on expert opinion, is provided in Figure 2.

### Conclusions

This report provides guidance on the use of bro-lucizumab for nAMD based on the opinion of the authors. The decision to use bro-lucizumab depends on a benefit-risk assessment. Patients who receive bro-lucizumab should be educated on the signs and symptoms of IOI after bro-lucizumab, the possible time course of IOI, and the need to immediately return to the clinic if any signs or symptoms arise. Based on recommendations from No-vartis, bro-lucizumab should not be administered more frequently than every 2 months after the initial three loading doses. Before each injection of bro-lucizumab, physicians should assess the anterior and posterior seg-ments of the eye for signs of inflammation. If inflam-mation is detected, bro-lucizumab should be discontinued, and a full examination should be conducted to charac-terize the location and severity of the inflammation for the purpose of guiding treatment decisions. Treatment of IOI after bro-lucizumab should be prompt and intensive. Physicians should be aggressive in treating possible inflammation in the posterior segment of the eye.

**Key words:** bro-lucizumab, intraocular inflamma-tion, retinal vasculitis, retinal vascular occlusion, occlusive retinal vasculitis, adverse events, neovascul-ar age-related macular degeneration.

### Acknowledgments

Medical writing support was provided by Ann Todd (IMPRINT Science, New York, NY) and was funded by Novartis Pharma AG. This manuscript was developed in accordance with Good Publication Practice (GPP3) guide-

lines. The authors had full control of the content and made the final decision on all aspects of this publication.

### References

1. Boulanger-Scemama E, Querques G, About F, et al. Ranibizumab for exudative age-related macular degeneration: a five year study of adherence to follow-up in a real-life setting. *J Fr Ophthalmol* 2015;38:620–627.
2. Ehlken C, Helms M, Böhringer D, et al. Association of treat-ment adherence with real-life VA outcomes in AMD, DME, and BRVO patients. *Clin Ophthalmol* 2017;12:13–20.
3. MacCumber MW. Real-world injection intervals in wet AMD. *Retina Today* May/June 2020 Special Report.
4. Varano M, Eter N, Winyard S, et al. Current barriers to treat-ment for wet age-related macular degeneration (wAMD): find-ings from the wAMD patient and caregiver survey. *Clin Ophthalmol* 2015;9:2243–2250.
5. Okada M, Mitchell P, Finger RP, et al. Nonadherence or non-persistence to intravitreal injection therapy for neovascular age-related macular degeneration: a mixed-methods systematic review. *Ophthalmology* 2021;128:234–247.
6. Boyer DS, Heier JS, Brown DM, et al. A phase IIIb study to evaluate the safety of ranibizumab in subjects with neovascular age-related macular degeneration. *Ophthalmology* 2009;116:1731–1739.
7. Beovu. Prescribing Information. East Hanover, NJ: Novartis Pharmaceuticals Corporation; 2022.
8. Dugel PU, Koh A, Ogura Y, et al. HAWK and HARRIER: phase 3, multicenter, randomized, double-masked trials of bro-lucizumab for neovascular age-related macular degeneration. *Ophthalmology* 2020;127:72–84.
9. Nguyen QD, Das A, Do DV, et al. Bro-lucizumab: evolution through preclinical and clinical studies and the implications for the management of neovascular age-related macular degenera-tion. *Ophthalmology* 2020;127:963–976.
10. Baupal CR, Bodaghi B, Singer M, et al. Expert opinion on management of intraocular inflammation, retinal vasculitis, and/or vascular occlusion after bro-lucizumab treatment. *Oph-thalmol Retina* 2021;5:519–527.
11. Sharma A, Kumar N, Parachuri N, et al. Bro-lucizumab-related retinal vasculitis: emerging disconnect between clinical trials and real world. *Eye (Lond)* 2021;35:1292–1294.
12. Beovu® (bro-lucizumab): global use and safety information for healthcare professionals. Available at: <https://www.brolucizumab.info>. Accessed June 1, 2021.
13. Monés J, Srivastava SK, Jaffe GJ, et al. Risk of inflammation, retinal vasculitis, and retinal occlusion-related events with bro-lucizumab: post hoc review of HAWK and HARRIER. *Oph-thalmology* 2021;128:1050–1059.
14. Baupal CR, Spaide RF, Vajzovic L, et al. Retinal vasculitis and intraocular inflammation after intravitreal injection of bro-lucizumab. *Ophthalmology* 2020;127:1345–1359.
15. Witkin AJ, Hahn P, Murray TG, et al. Occlusive retinal vas-culitis following intravitreal bro-lucizumab. *J Vitreoretin Dis* 2020;4:269–279.
16. Jain A, Chea S, Matsumiya W, et al. Severe vision loss sec-ondary to retinal arteriolar occlusions after multiple intravitreal bro-lucizumab administrations. *Am J Ophthalmol Case Rep* 2020;18:100687.
17. Kondapalli SSA. Retinal vasculitis after administration of bro-lucizumab resulting in severe loss of visual acuity. *JAMA Ophthalmol* 2020;138:1103–1104.



18. Haug SJ, Hien DL, Uludag G, et al. Retinal arterial occlusive vasculitis following intravitreal brolocizumab administration. *Am J Ophthalmol Case Rep* 2020;18:100680.
19. Iyer PG, Peden MC, Suñer IJ, et al. Brolocizumab-related retinal vasculitis with exacerbation following ranibizumab retreatment: a clinicopathologic case study. *Am J Ophthalmol Case Rep* 2020;20:100989.
20. Antaki F, Vadboncoeur J. Retinal vasculitis after intravitreal injection of brolocizumab. *Can J Ophthalmol* 2022;57:e40.
21. Hikichi T. Three Japanese cases of intraocular inflammation after intravitreal brolocizumab injections in one clinic. *Jpn J Ophthalmol* 2021;65:208–214.
22. Kataoka K, Horiguchi E, Kawano K, et al. Three cases of brolocizumab-associated retinal vasculitis treated with systemic and local steroid therapy. *Jpn J Ophthalmol* 2021;65:199–207.
23. Maruko I, Okada AA, Iida T, et al. Brolocizumab-related intraocular inflammation in Japanese patients with age-related macular degeneration: a short-term multicenter study. *Graefes Arch Clin Exp Ophthalmol* 2021;259:2857–2859.
24. Holz FG, Heinz C, Wolf A, et al. [Intraocular inflammation with brolocizumab use: patient management-diagnosis-therapy]. *Ophthalmologie* 2021;118:248–256.
25. Sharma A, Kumar N, Parachuri N, et al. Brolocizumab-foreseeable workflow in the current scenario. *Eye (Lond)* 2021;35:1548–1550.
26. Singer M, Albin TA, Seres A, et al. Clinical characteristics and outcomes of eyes with intraocular inflammation after brolocizumab: post hoc analysis of HAWK and HARRIER. *Ophthalmol Retina* 2022;6:97–108.
27. Khanani AM, Zarbin MA, Barakat MR, et al. Safety outcomes of brolocizumab in neovascular age-related macular degeneration: results from the IRIS registry and Komodo Healthcare Map. *JAMA Ophthalmol* 2022;140:20–28.
28. Dugel PU, Singh RP, Koh A, et al. HAWK and HARRIER: ninety-six-week outcomes from the phase 3 trials of brolocizumab for neovascular age-related macular degeneration. *Ophthalmology* 2021;128:89–99.
29. Bulirsch LM, Saßmannshausen M, Nadal J, et al. Short-term real-world outcomes following intravitreal brolocizumab for neovascular AMD: SHIFT study. *Br J Ophthalmol*:2021. Published online April 12, 2021.
30. Kessler LJ, Mayer CS, Son HS, et al. Bilateral vasculitis following intravitreal brolocizumab injection (in German). *Ophthalmologie* 2022;119:93–97.
31. Riedel AM, Lackerbauer C, Lohmann CP, Ulbig M. [Bilateral occlusive vasculitis after intravitreal injection of brolocizumab in neovascular age-related macular degeneration]. *Ophthalmologie* 2022;119:75–78.
32. Summary Beovu of Product Characteristics. Dublin, Ireland: Novartis Europharm Limited; 2022.
33. Rayess N, Rahimy E, Storey P, et al. Postinjection endophthalmitis rates and characteristics following intravitreal bevacizumab, ranibizumab, and aflibercept. *Am J Ophthalmol* 2016;165:88–93.
34. Jabs DA, Nussenblatt RB, Rosenbaum JT, Standardization of Uveitis Working Group. Standardization of uveitis nomenclature for reporting clinical data. Results of the first international workshop. *Am J Ophthalmol* 2005;140:509–516.
35. Angerer MPM, Neuburger M, Hille K, Horn PC. [Vaso-occlusive retinitis following intravitreal injection of brolocizumab]. *Ophthalmologie* 2021;118:1048–1050.
36. Enríquez AB, Bauml CR, Crane AM, et al. Early experience with brolocizumab treatment of neovascular age-related macular degeneration. *JAMA Ophthalmol* 2021;139:441–448.
37. Kaupke N, Stübiger N, Dulz S, et al. [Acute unilateral loss of vision after intravitreal injection of a VEGF inhibitor]. *Ophthalmologie* 2021;118:1276–1279.
38. Leclaire MD, Laueremann J, Alten F, Eter N. [Intraocular inflammation with occlusive retinal vasculitis following intravitreal injection of brolocizumab]. *Ophthalmologie* 2022;119:296–299.
39. Narayanan R, Tyagi M, Gupta SR, et al. Immediate onset of sterile endophthalmitis with hypopyon after intravitreal brolocizumab in a case of polypoidal choroidal vasculopathy. *Indian J Ophthalmol* 2021;69:469–470.